



Manajemen Anestesi Perioperatif Pasien Kehamilan Mola dengan Hipertiroidisme dan COVID-19 yang Menjalani Kuretase Hisap

Bagus Fajar Rochman¹, Mahendratama Purnama Adhi¹, Iwan Nuryawan¹

1. Departemen Anestesiologi dan Terapi Intensif, Fakultas Kedokteran, Universitas Lambung Mangkurat/RS Ulin, Banjarmasin, Indonesia

**penulis korespondensi*

DOI: 10.55497/majanestcricar.v39i3.227

ABSTRAK

Latar belakang: Insiden kehamilan mola meningkat selama pandemi COVID-19. Kehamilan mola dapat menyebabkan hipertiroidisme dan jika tidak segera ditangani dapat memperburuk kondisi pasien. Kehamilan mola disertai hipertiroidisme dan infeksi SARS-CoV-2 menjadi tantangan bagi ahli anestesi untuk mencegah terjadinya komplikasi krisis tiroid dan perburukan COVID-19 dalam tatalaksana perioperatif.

Presentasi kasus: Seorang wanita 38 tahun dirujuk ke rumah sakit dengan usia kehamilan 11-12 minggu disertai perdarahan pervaginam. Dua minggu sebelum masuk rumah sakit pasien mengeluhkan demam dan 3 hari terakhir mengalami batuk dan pilek. Pasien tidak memiliki riwayat kontak dengan pasien COVID-19. Pada pemeriksaan fisik didapatkan tekanan darah 160/90 mmHg, denyut jantung 114 kali per menit, frekuensi pernapasan 18 kali per menit, SpO₂ 97% dengan udara ruang, dan suhu tubuh 37,4°C. Pemeriksaan laboratorium menunjukkan kadar hemoglobin 9,2 g/dl, kadar hCG > 1.000.000 mIU/ml, dan uji fungsi tiroid menunjukkan hipertiroidisme. Pemeriksaan USG obstetri menunjukkan kehamilan mola. Skor Burch-Wartofsky diperoleh hasil 20. Hasil tes real-time transcription-polymerase chain reaction (RT-PCR) positif untuk SARS-CoV-2. Sebelum operasi pasien mendapatkan terapi propiltiourasil (PTU) 100 mg oral per 8 jam dan propranolol 20 mg oral sekali sehari. Tindakan kuretase hisap dilakukan keesokan harinya dengan anestesi spinal menggunakan bupivakain hiperbarik 0,5% 10 mg. Pembedahan berlangsung selama 75 menit tanpa penyulit. Evaluasi hingga 30 hari setelah kuretase tidak didapatkan komplikasi krisis tiroid dan perburukan COVID-19.

Kesimpulan: Disregulasi imun bawaan akibat hipertiroidisme dapat memperburuk perjalanan klinis COVID-19, dan sebaliknya, infeksi SARS-CoV-2 dapat menyebabkan gangguan hormon tiroid. Anestesi spinal aman dilakukan pada pasien dengan kehamilan mola yang disertai hipertiroidisme dan COVID-19.

Kata kunci: anestesi spinal, COVID-19, hipertiroidisme, kehamilan mola, SARS-CoV-2



Perioperative Anesthetic Management of Molar Pregnancy Patients with Hyperthyroidism and COVID-19 Underwent Suction Curettage

Bagus Fajar Rochman¹, Mahendratama Purnama Adhi¹, Iwan Nuryawan¹

1. Department of Anesthesiology and Intensive Care, Faculty of Medicine, Universitas Lambung Mangkurat/Ulin Hospital, Banjarmasin, Indonesia

*corresponding author

ABSTRACT

Background: The incidence of molar pregnancies has increased during the COVID-19 pandemic. Molar pregnancy can cause hyperthyroidism and if not treated immediately can worsen the patient's condition. A molar pregnancy with hyperthyroidism infected with SARS-CoV-2 poses a challenge for anesthesiologists in perioperative management to prevent complications of thyroid crisis and worsening of COVID-19.

Case presentation: A 38-year-old woman was referred to our hospital with a gestational age of 11-12 weeks with vaginal bleeding. Since 2 weeks before being admitted to the hospital the patient complained of fever and the last 3 days had a cough and runny nose. She had no history of contact with COVID-19 patient. On physical examination, her blood pressure was 160/90 mmHg, heart rate was 114 beats per minute, respiratory rate was 18 times per minute, SpO₂ was 97% on room air, and body temperature was 37.4°C. Laboratory tests revealed hemoglobin level of 9.2 g/dl, hCG levels > 1,000,000 mIU/ml, and thyroid function tests showed hyperthyroidism. Obstetric ultrasound examination revealed a molar pregnancy. A Burch-Wartofsky score was 20. The real-time transcription-polymerase chain reaction (RT-PCR) test were positive for SARS-CoV-2. In the pre-operative period, the patient was treated with 100 mg of propylthiouracil (PTU) orally every 8 hours and 20 mg of propranolol orally once a day. We performed the curettage suction on the next day under spinal anesthesia using 10 mg of 0.5% hyperbaric bupivacaine. Surgery lasted 75 minutes and performed uneventfully. Evaluation up to 30 days after curettage we found no complications of thyroid crisis and worsening of COVID-19.

Conclusion: Innate immune dysregulation due to hyperthyroidism may worsen the clinical course of COVID-19 patients, and conversely, SARS-CoV-2 infection can cause thyroid hormone disorders. Spinal anesthesia can be safely performed in patients with molar pregnancy accompanied by hyperthyroidism and COVID-19.

Keywords: COVID-19, hyperthyroidism, molar pregnancy, SARS-CoV-2, spinal anesthesia

INTRODUCTION

The incidence of molar pregnancies has reportedly increased during the coronavirus disease 2019 (COVID-19) pandemic due to late diagnosis because of lockdowns.¹ Vaginal bleeding often accompanies a molar pregnancy at 6-16 weeks of gestation.² In addition, a molar pregnancy can lead to hyperthyroidism which is triggered by the excessive release of human chorionic gonadotropin (hCG) levels.³ This condition can worsen the patient's condition. Symptoms of hyperthyroidism in molar pregnancies can range from sub-clinical hyperthyroidism to thyrotoxicosis and life-threatening thyroid crises.² Evacuation of the molar pregnancy by suction curettage is necessary to reduce thyroid hormone levels.

Thyroid disease can predispose to severe acute respiratory syndrome coronavirus 2 (SARS-CoV-2) infection and vice versa.^{4,5} In addition, surgery on patients infected with SARS-CoV-2 increases the risk of pulmonary complications, morbidity and mortality.⁶ To the best of our knowledge there is only one report about molar pregnancy accompanied with hyperthyroidism and COVID-19. Rigi et al. reported that after curettage, the patient had a thyrotoxicosis and respiratory distress requiring mechanical ventilation.⁷ Anesthetic management in molar pregnancy with COVID-19 poses a challenge for anesthesiologists to prevent complications of thyroid crisis, worsening of COVID-19, and transmission of SARS-CoV-2 to the healthcare workers (HCWs). Here, we describe the management of anesthesia in a patient with a molar pregnancy accompanied by hyperthyroidism and COVID-19.

CASE PRESENTATION

We have obtained written consent from the patient to be included in this report. A 38-year-old woman, weighing 60 kg, height 150 cm, was referred to our hospital with 11-12 weeks of pregnancy with vaginal bleeding. The patient complained of hyperemesis early in pregnancy. In the last 2 weeks, she had a fever. She had a cough and a runny nose for 3 days before being admitted to the hospital. The patient was diagnosed with mild COVID-19 after the

result of the real-time transcription polymerase chain reaction (RT-PCR) test was positive for SARS-CoV-2. She had a history of twice normal deliveries and one abortion. She had no history of contact with COVID-19 patients. The patient had no history of other coexisting systemic diseases. On physical examination, her blood pressure was 160/90 mmHg, heart rate was 114 beats per minute (bpm), respiratory rate was 18 times per minute, SpO₂ was 97% with room air, and body temperature was 37.4°C. Laboratory tests revealed hemoglobin levels of 9.2 g/dl, β hCG levels >1,000,000 mIU/ml, free triiodothyronine (FT3) 13.72 pmol/l, free thyroxine (FT4) 21.95 pmol/l, and thyroid stimulating hormone (TSH) 0.017 mIU/ml (table 1). Obstetric ultrasound examination revealed a honeycomb appearance in accordance with molar pregnancy. A Burch-Wartofsky score was 20, which suggested thyroid storm unlikely. The patient was treated with 20 mg of propranolol orally once a day and 100 mg of propylthiouracil (PTU) orally every 8 hours a day before curettage procedure. We performed suction curettage on the next day.

Preventing the transmission of SARS-CoV-2 to HCWs, we perform suction curettage in a negative-pressure operating room specially designed for the surgery of COVID-19 patients. All HCWs involved are wearing level 3 personal protective equipment (PPE). When the patient arrived in the operating room, a standard non-invasive monitor was installed (her blood pressure was 170/93 mmHg, heart rates was 95 bpm, SpO₂ was 98% with 3 ml oxygen through nasal cannula, and her body temperature was 37°C). After preloading with 500 ml of ringer's lactate solution, we performed spinal anesthesia at the L3-4 interspace with intrathecal administration of 2 ml 0.5% hyperbaric bupivacaine. Five minutes after spinal anesthesia, it obtained a complete motor block with a sensory block height at the T8 level. The patient was sedated with 3 mg of midazolam intravenously (Ramsay score 4). Intraoperative hemodynamic was stable with a range of systolic blood pressure was 120 and 130 mmHg, MAP was 80 - 90 mmHg, heart rates were 80-100 bpm, and SpO₂ 98 - 99% with 3 ml oxygen flow through the nasal cannula covered with a surgical mask. The surgery lasted 75 minutes with 800 ml of blood loss, 2000 ml of

hydatidiform mole tissue, and 50 ml of urine output. Intraoperative blood loss was replaced by giving 350 ml of whole blood product and 2000 ml of ringer's lactate solution (figure 1). After surgery, we transferred the patient to the COVID-19 ICU room, and she was shifted to the isolation ward on postoperative day 2. Postoperatively, PTU was switched with 20 mg of oral methimazole and propranolol was continued. Postoperative analgesia by administering 100 mg of tramadol intravenously every 12 hours for

a day and 30 mg of ketorolac every 8 hours for 3 days, using the numerical rating scale (NRS) obtained pain scores at rest and activity was 1 and 2, respectively. The patient was discharged on postoperative day 7 and underwent self-isolation. There was no clinical worsening due to hyperthyroidism and COVID-19 during hospitalization. After the patient discharged, we conducted a clinical evaluation up to day 30 post curettage by phone, and we found no complications related to COVID-19.

Table 1. Summary of laboratory results

Laboratory examination	Normal range	Pre-operative	Postoperative day 4
Hemoglobin level, gr/dL	12 - 16	9.2	8.3
White blood cell count, x 10 ³ /ml	4.0 - 10.5	11	11.9
Platelet count, x 10 ³ /ml	150 - 450	197	133
Neutrophyl count, x 10 ³ /ml	2.50 - 7.00	9.57	6.14
Lymphocyte count, x 10 ³ /ml	1.25 - 4.00	1.13	2,73
Neutrophyl-lymphocyte ratio	1 - 3	8.46	2.24
β hCG, mIU/ml	< 1	>1,000,000	151,207
FT4, pmol/l	10.60 - 19.40	21.95	10.83
FT3, pmol/l	4.00 - 8.30	13.72	N/A
TSH, mIU/ml	0.55 - 4.78	0.017	0.006
C-reactive protein, mg/L	0 - 3	8.3	6.2
D-dimer, mg/L	0 - 0.55	2.55	N/A

β hCG; β human chorionic gonadotropin, FT4; free thyroxine, FT3; free triiodothyronine, TSH; thyroid stimulating hormone, N/A; not available

DISCUSSION

A molar pregnancy is a form of gestational trophoblastic disease that causes an abnormal increase in the levels of hCG.³ The subunit of β hCG has a similar structure to TSH so that it can bind to the TSH receptor in thyroid follicular cells.² As a result, thyroid hormone levels will increase and TSH levels decrease. SARS-CoV-2 infection has been reported to cause thyroid dysfunction. The inflammatory response and direct infection of SARS-CoV-2 through the ACE-2 receptor in the thyroid gland cause thyroid dysfunction in COVID-19.^{8,9} Lania et al. reported that from 287 COVID-19 patients, 20.2% of patients had thyrotoxicosis, 5.2% had hypothyroidism, and 74.65% had normal thyroid function.⁵ Wang

et al. reported that total triiodothyronine (TT3) and TSH levels were lower in COVID-19 patients compared to healthy patients.⁸ The results show that thyroid dysfunction in COVID-19 patients can be hyperthyroidism or hypothyroidism, so it is not known for certain whether SARS-CoV-2 infection will worsen or ease hyperthyroidism in molar pregnancy patients. However, hyperthyroidism causes an increase in inflammatory factors such as IL-6, IL-12, IL-18, fibrinogen, plasminogen activator inhibitor 1, von Willebrand factor, and vascular cell adhesion molecule-1, which can trigger a hypercoagulable state that can exacerbate the clinical symptoms of COVID-19 and increase the incidence of cardiovascular complications.¹⁰ One published case of a hyperthyroid patient

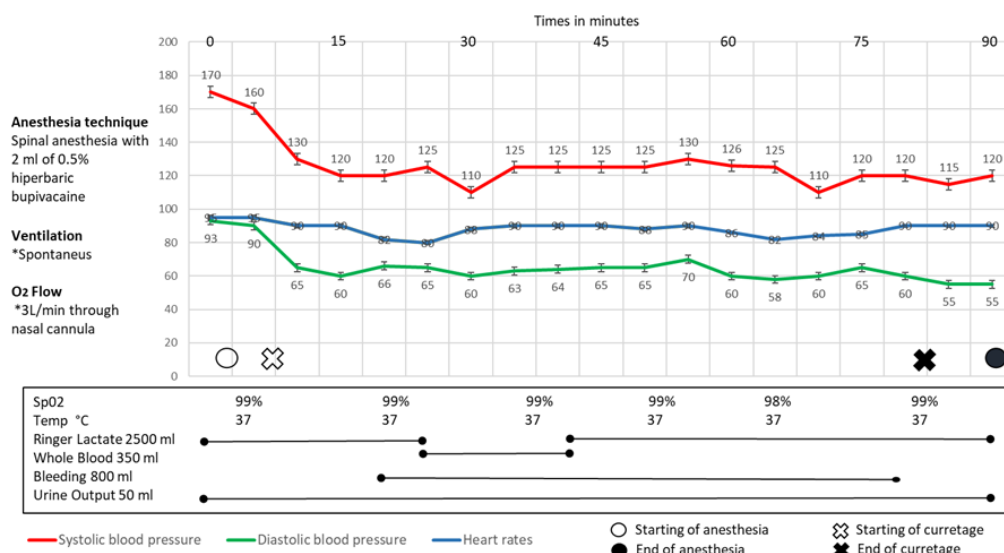


Figure 1. Intraoperative Hemodynamic Monitoring

due to a molar pregnancy with COVID-19, after curettage the patient experienced tachycardia, hyperthermia, and severe respiratory distress that required mechanical ventilation.⁷ Lung CT scan showed bilateral ground glass patches. In that case, the patient did not receive anti-thyroid drugs so that the severe pulmonary complications that occurred in this case may be caused by uncontrolled hyperthyroidism which causes the release of inflammatory factors and innate immune dysregulation, thus aggravate the clinical course of COVID-19 in that patient. Proper diagnosis, perioperative management, and appropriate anesthetic strategies are needed in the management of patients with hyperthyroidism due to molar pregnancy. A molar pregnancy with high levels of hCG should be suspected of having thyroid hormone disorders. Increasing 10,000 mIU/mL serum hCG, will increase 0.1 nG/dL of FT4 and decrease 0.1 mIU/ml of TSH.^{2,11} The clinical symptoms of hyperthyroidism occur in an increase in serum hCG of over 200,000 mIU/ml.² An increase in thyroid hormone will stimulate the sympathetic activity so that an increase in heart rate, blood pressure, an increase in the basal metabolic rate, and tremors are the most common clinical signs of hyperthyroidism.¹² In our case, we diagnosed the patient with hyperthyroidism based on clinical symptoms and low TSH results, with elevated T3 and T4. However, with the

assessment using the Burch Wartofsky scoring the patient did not have a thyroid crisis.¹³ The principle of preoperative management in these patients is to prevent uncontrolled hyperthyroidism which can lead to the thyroid crisis and dysregulation of the innate immune response which can worsen COVID-19. It can be done by reducing the synthesis of thyroid hormones, block the action of thyroid hormone, inhibits the conversion of T4 to T3, and eliminate the trigger factors. Thyroid hormone synthesis can be inhibited with antithyroid drugs such as PTU or methimazole. For emergency surgery, preoperative PTU is preferred because in addition to inhibiting thyroid hormone synthesis, it can also prevent the conversion of T4 to T3.^{2,13} Thyroid hormone tests should be done regularly every 4 weeks. Anti-thyroid drugs administration can be discontinued when thyroid function is normal.¹⁴ Sympathetic stimulation due to increased thyroid hormone can be treated with beta-blockers. Besides blocking the sympathetic effects, propranolol also prevents the peripheral conversion of T4 to T3. However, the use of propranolol should be avoided in hyperthyroid patients with heart failure.¹⁵ Because hyperthyroidism in molar pregnancies results from increased of β hCG, prompt evacuation of a molar pregnancy by suction curettage can rapidly decrease levels of β hCG as well as thyroid hormone.

General or regional anesthesia can be performed in patients with hyperthyroidism. Neuraxial anesthesia is the proper option because it can reduce blood pressure and heart rate through sympathetic block, and provide adequate postoperative pain control. Another advantage of neuraxial anesthesia is the avoidance of sympathetic stimulation due to manipulation during laryngoscopy and intubation.³ Moreover, considering that monitoring clinical symptoms is an important component in diagnosing thyroid crisis, so maintaining patient awareness during surgery has the advantage of early detection of thyroid crisis.¹⁶ However, the patient's anxiety during surgery is also can precipitate a thyroid crisis. Moderate sedation during surgery with the administration of midazolam in patients under neuraxial anesthesia can ease patient anxiety but still facilitate clinical evaluation of patient consciousness.

In this case, we performed spinal anesthesia with the consideration of surgical procedures on the lower abdomen with a short duration of surgery, and to avoid aerosol-generating procedures. Spinal anesthesia can be safely performed in hyperthyroid patients without concomitant heart failure. In addition, spinal anesthesia has the advantage of being easier to perform, faster onset of action with higher efficacy compared to epidural anesthesia,¹⁶ so as to reduce the exposure time between patients with HCWs, considering that the patient suffers from COVID-19. Hydration with intravenous crystalloid administration before spinal anesthesia may prevent hypotension. Maintenance of anesthesia during surgery should ensure hemodynamic stability, maintain intravascular volume and proper oxygenation.¹¹ Inadequate analgesia can lead to a thyroid crisis. To ensure optimal postoperative pain control, we used a multimodal analgesia approach with tramadol and ketorolac administration, as well as rigorous assessment of periodic pain scales. The Coidsurg collaborative research showed that surgery on patients with COVID-19 had a 30-day postoperative mortality of 23.8% and had pulmonary complications of 51.2%.⁶ Furthermore, Coidsurg collaborative suggests that surgery in patients with COVID-19 should be postponed for at least 7 weeks after SARS-

CoV-2 infection.¹⁷ However, in our case, the patient had to undergo suction curettage immediately to eliminate the causative factor of hyperthyroidism. Surgery, tissue damage, psychological stress can lead to an increase in inflammatory responses.¹⁸ In addition, our patient had elevated thyroid hormone levels which could lead to dysregulation of the innate immune response.⁴ This surgical inflammatory response and dysregulation of the innate immune response may increase the risk of worsening COVID-19. Rigi et al. reported a case of post-curettage due to a molar pregnancy accompanied by hyperthyroidism and COVID-19 who experienced severe pulmonary complications that required mechanical ventilation.⁷ However, the patient experienced clinical improvement and was discharged from hospital. In our case, clinical symptoms such as fever occurred 2 weeks before the patient was admitted to the hospital, so the patient is probably in the recovery phase of COVID-19. This factor may have played a role in providing excellent outcomes in our patients. Even though the patient had been experiencing COVID-19 symptoms for the previous two weeks, the RT-PCR test result was still positive. Patients with thyroid dysfunction require a longer time for viral nucleic acid clearance.⁸ Monitoring of up to 30 days postoperatively we found no clinical worsening related to COVID-19 as well as complications due to hyperthyroidism.

CONCLUSION

Hyperthyroidism should be considered in patients with molar pregnancies. Administration of anti-thyroid drugs, beta-blockers should be given immediately preoperatively and continued postoperatively to prevent uncontrolled hyperthyroidism and thyroid crisis. In patients infected with SARS-CoV-2, innate immune dysregulation due to hyperthyroidism may worsen the clinical course of COVID-19, and conversely, SARS-CoV-2 infection can cause thyroid hormone disorders. Spinal anesthesia in cases of hyperthyroidism due to molar pregnancy with COVID-19 undergoing suction curettage can be performed safely and has the advantage of inhibiting sympathetic stimulation, is easy to administer, has a rapid onset of action, and does

not cause aerosolization, thus reducing the risk of transmission of SARS-CoV-2 to healthcare workers.

REFERENCES

1. Aiob A, Naskovica K, Sharon A, Bornstein J. A possible association between hydatidiform mole and the COVID-19 pandemic: A retrospective cohort study. *Gynecol Oncol*. 2021;161(2):454-7.
2. Blick C, Schreyer KE. Gestational Trophoblastic disease-induced thyroid storm. *Clin Pract Cases Emerg Med*. 2019;3(4):409-12.
3. Swaminathan S, James RA, Chandran R, Joshi R. Anaesthetic implications of severe hyperthyroidism secondary to molar pregnancy: A case report and review of literature. *Anesth Essays Res*. 2017;11(4):1115-7.
4. Hariyanto TI, Kurniawan A. Thyroid disease is associated with severe coronavirus disease 2019 (COVID-19) infection. *Diabetes Metab Syndr*. 2020;14(5):1429-30.
5. Lania A, Sandri MT, Cellini M, Mirani M, Lavezzi E, Mazziotti G. Thyrotoxicosis in patients with COVID-19: the THYRCOV study. *Eur J Endocrinol*. 2020;183(4):381-7.
6. Nepogodiev D, Bhangu A, Glasbey JC, Li E, Omar OM, Simoes JF, et al. Mortality and pulmonary complications in patients undergoing surgery with perioperative SARS-CoV-2 infection: an international cohort study. *The Lancet*. 2020 Jul 4;396(10243):27-38.
7. Rigi S, Janghorban R, Azarkish F, Aminifard M, Bozorgzadeh S, Zahirnia M, et al. The first suspected case of corona-virus in the mole of hydatidiform in southern Sistan-Baluchestan, Iran. *Authorea*. 2020.
8. Wang W, Su X, Ding Y, Fan W, Zhou W, Su J, et al. Thyroid Function Abnormalities in COVID-19 Patients. *Front Endocrinol*. 2021;19(11):1-11.
9. Khatri A, Charlap E, Kim A. Subacute thyroiditis from COVID-19 infection: A case report and review of literature. *Eur Thyroid J*. 2021;9(6):324-8.
10. Duntas L, Jonklaas J. COVID-19 and thyroid diseases: a bidirectional impact. *Journal of the Endocrine Society*. 2021;5(8):1-11.
11. Sriramka B, Acharya R. Low-dose spinal anesthesia: A safe option in molar pregnancy with thyrotoxicosis. *Indian Journal of Clinical Practice*. 2020;30(8):760-2.
12. Tankeu AT, Azabji-Kenfack M, Nganou CN, Ngassam E, Kuate-Mfeukeu L, Mba C, et al. Effect of propranolol on heart rate variability in hyperthyroidism. *BMC Res Notes*. 2018;11(1):151.
13. Akamizu T. Thyroid Storm: A Japanese perspective. *Thyroid*. 2018;28(1):32-40.
14. Simes BC, Mbanaso AA, Zapata CA, Okoroji CM. Hyperthyroidism in a complete molar pregnancy with a mature cystic ovarian teratoma. *Thyroid Res*. 2018;11(12):1-5.
15. Abubakar H, Singh V, Arora A, Alsunaid S. Propranolol-induced circulatory collapse in a patient with thyroid crisis and underlying thyrocardiac disease: A word of caution. *J Investig Med High Impact Case Rep*. 2017;5(4):1-6.
16. Park S, Choi S, Jeong J, Kim J. Spinal anesthesia for urgent cesarean section in a patient with uncontrolled hyperthyroidism due to graves' disease - A case report. *Anesth Pain Med (Seoul)*. 2020;15(3):319-24.
17. COVIDSurg Collaborative; GlobalSurg Collaborative. Timing of surgery following SARS-CoV-2 infection: an international prospective cohort study. *Anaesthesia*. 2021;76(6):748-58.
18. Margraf A, Ludwig N, Zarbock A, Rossaint J. Systemic inflammatory response syndrome after surgery: Mechanisms and protection. *Anesth Analg*. 2020;131(6):1693-707.